World Journal of Urology (2020) 38:939–948
https://doi.org/10.1007/s00345-019-02846-z

ORIGINAL ARTICLE

^{68}Ga-PSMA PET/CT compared with MRI/CT and diffusion-weighted MRI for primary lymph node staging prior to definitive radiotherapy in prostate cancer: a prospective diagnostic test accuracy study

Lars J. Petersen[1,2] · Julie B. Nielsen[1,2] · Niels C. Langkilde[2,3] · Astrid Petersen[4] · Ali Afshar-Oromieh[5] · Nandita M. De Souza[6] · Katja De Paepe[6] · Rune V. Fisker[1,7] · Dennis T. Arp[8] · Jesper Carl[8,9] · Uwe Haberkorn[10,11] · Helle D. Zacho[1,2]

Received: 21 January 2019 / Accepted: 6 June 2019 / Published online: 12 June 2019
© Springer-Verlag GmbH Germany, part of Springer Nature 2019

Abstract

Background The aim was to compare the diagnostic accuracy of ^{68}Ga-PSMA PET/CT with conventional cross-sectional imaging and diffusion-weighted MRI (DW-MRI) for detecting lymph node metastasis (LNM) to stage prostate cancer patients. Twenty consecutive, newly- diagnosed prostate cancer patients were prospectively enrolled and underwent ^{68}Ga-PSMA-11 PET/CT, anatomical MRI or contrast-enhanced CT, and DW-MRI prior to laparoscopic, template-based, extended lymph node dissection. Histopathological findings served as the reference test.

Results Histopathology showed LNM in 13 of 20 patients (19 high-risk, 1 intermediate risk). Five patients had metastasis-suspected lymph nodes on ^{68}Ga-PSMA PET/CT. Patient-based analysis showed that the sensitivity and specificity for detecting LNM were 39% and 100% with ^{68}Ga-PSMA PET/CT, 8% and 100% with MRI/CT, and 36% and 83% with DW-MRI, respectively. The positive and negative predictive values were 100% and 49% with ^{68}Ga-PSMA PET/C, 100% and 37% with MRI/CT, and 80% and 42% with DW-MRI. Of 573 dissected lymph nodes, 33 were LNM from 26 regions. True-positive LNM on ^{68}Ga-PSMA PET/CT was 9–11 mm in diameter, whereas false-negative LNM had a median diameter of 4 mm, with only 3 of 30 lymph nodes being larger than 10 mm. LNM were positive for PSMA by immunostaining.

Conclusions The sensitivity of ^{68}Ga-PSMA PET/CT was notably better than that of MRI/CT and comparable to that of DW-MRI. Some false positive findings with DW-MRI reduced its specificity and positive predictive value compared with those of ^{68}Ga-PSMA PET/CT and MRI/CT.

Keywords Anatomical cross-sectional imaging · Diagnostic accuracy · Prostatic neoplasm · PSMA PET/CT · Staging

Background

Patients with newly diagnosed prostate cancer (PCa) and unfavorable disease characteristics should undergo staging for bone and lymph node metastasis (LNM) according to most guidelines, e.g., the European Association of Urology (EAU) [1–3]. These guidelines consistently recommend anatomical imaging with computed tomography (CT) or magnetic resonance imaging (MRI) for LNM staging despite the modest positive and negative predictive values of anatomical imaging methods for LNM [4].

Gallium-68-labeled prostate-specific membrane antigen positron emission tomography/computer tomography (^{68}Ga-PSMA PET/CT) is a contemporary functional imaging modality for the detection of PCa and PCa metastases [5, 6]. The technical and clinical developments of ^{68}Ga-PSMA PET/CT are rapidly evolving, particularly in evaluating biochemical recurrence [6, 7]. There are some data on ^{68}Ga-PSMA PET/CT for LNM staging as part of the initial workup [8, 9], though mostly retrospective trials with histopathological reference and trials without a proper reference test [10].

The purpose of this prospective, diagnostic test accuracy study was to compare the diagnostic performance of ^{68}Ga-PSMA PET/CT with that of anatomical imaging and diffusion-weighted MRI (DW-MRI) for detecting LNM in newly diagnosed, intermediate- and high-risk PCa patients

✉ Lars J. Petersen
lajp@rn.dk

Extended author information available on the last page of the article

undergoing lymph node dissection prior to curative intent radiotherapy.

Methods

Study design

This diagnostic test accuracy study was conducted in compliance with the Standards for Reporting of Diagnostic Accuracy Studies (STARD) [11]. The study followed the rules of Good Clinical Practice (GCP) and was monitored by the GCP Unit at Aarhus and Aalborg University Hospitals.

Patients

Consecutive eligible patients with newly diagnosed EAU intermediate-risk (limited to those with predominantly Gleason pattern 4) or high-risk PCa [1] were prospectively enrolled at one site (Aalborg University Hospital) from May 2015 to October 2016. All patients were referred for extended lymph node dissection (eLND) prior to definitive (curative) radiotherapy as part of clinical practice. Aalborg University Hospital serves a population of 600 000 people. Patients had to be at least 18 years of age and provide oral and written informed consent. The exclusion criteria were: (1) bone metastasis on bone scintigraphy (thus ineligible for curative therapy); (2) prior cancer within 5 years except for curatively treated non-melanoma skin cancer (the accuracy methodology for the diagnostic test was planned for PCa detection only); (3) known allergy to any of the constituents of the PET tracer or any contrast media used; (4) weight > 180 kg (scanner limitation); or (5) any medical condition that may interfere with study procedures (e.g., claustrophobia for MRI, drug addiction or mental disorders).

Overview of imaging

All patients underwent a ^{68}Ga-PSMA PET with low-dose CT and an MRI (default) or a PET with a diagnostic CT as previously described for patients with biochemical recurrence in another prospective trial with ^{68}Ga-PSMA [12]. If a patient was ineligible to undergo MRI, a contrast-enhanced CT was performed with the PET scan.

^{68}Ga-PSMA PET/CT

The ^{68}Ga-PSMA (PSMA-11, ABX GmbH, Radeberg, Germany) was administered as an intravenous bolus injection of 2 MBq/kg of body weight. The PET/CT scan was performed 60 min postinjection (mean time, 60 ± 9 min; range 53–97 min) on a VCT discovery True 64 PET/CT (GE Healthcare, Chicago, Illinois, USA). The scan covered the neck to mid-thigh, encompassing 5–7 bed positions at 4 min per bed position. For the unenhanced low-dose CT, the parameters were 120 keV and 10–150 mA. The slice thickness for both protocols was 0.625 mm.

MRI and DW-MRI

MRI and DW-MRI were performed in accordance with the European Society of Urogenital Radiology (ESUR) MRI guidelines for bone and LNM in PCa [13]. In brief, T1- and T2-weighted and short tau inversion recovery (STIR) sequences were used for MRI of the spine and pelvis, whereas DW-MRI was performed using *b* values of 0 and 600 s/mm^2 using a 3-T MRI scanner (Ingenia 3.0T, Philips Healthcare, Best, The Netherlands). The DW-MRI images were reconstructed as whole-body three-dimensional maximum intensity projection (MIP) images. The details of MRI acquisition were recently published [12].

Image interpretation

Images from the ^{68}Ga-PSMA PET/CT were independently read by two experienced nuclear medicine physicians (HDZ and AAO) categorized as highly experienced according to a recent classification [14]. DW-MRI images were read by two experienced radiologists (NDS and KDP) with notable experience with functional MRI in PCa. MRI/CT images were read by one experienced MRI radiologist with more than 20 years of experience with MRI/CT and who is section head of MRI (RVF). All readers were board-certified in their respective fields and most are deeply engaged in prostate cancer imaging in multidisciplinary groups or activities [7, 15].

No clinical information except the eligibility criteria was available for the readers. All suspected pathological lesions were classified as positive (definite or equivocal for metastasis). Patients without any positive lesions were considered without metastasis. No protocol-specific criteria were used to define lesions as malignant on ^{68}Ga-PSMA PET/CT or DW-MRI, but the readers followed the generally accepted current reading criteria [16, 17]. The criteria for classifying LNM on MRI/CT required a short-axis > 10 mm. After individual readings with ^{68}Ga-PSMA PET/CT and DW-MRI, the findings from each reader were compared, and a consensus was reached. Positive lesions were anatomically classified as confined to (1) the prostatic bed, (2) lymph nodes within the field of eLND, (3) lymph nodes outside the field of eLND, (4) bone metastases, and (5) visceral lesions. The field of view of DW-MRI was limited to the spine and pelvis.

Extended lymph node dissection

Trained urological surgeons were responsible for eLND, which was performed using a laparoscopic, robotic approach. If the eLND was done by fellows in training, one board-certified surgeon assisted during surgery. The surgeons were blinded to the results of the preoperative imaging. The eLND procedure was performed using a standard template of the intrapelvic area comprising the common iliac artery, external iliac, internal iliac, and obturator fossa area on the right and left sides (eight regions in total).

Histopathology

The lymph node specimens were received in separate containers from a median of seven regions (range 4–8). After fixation, the lymph nodes were dissected, bivalved if > 3 mm, and embedded separately, and the residual fibrofatty tissue was embedded altogether. The specimens were sliced with a microtome into 4- to 5 µm thick sections and stained with hematoxylin and eosin (HE). The diagnosis was based on the HE-stained slides or, if necessary, on immunohistochemistry (ICH) (PSA; Novocastra, clone 35H9, dilution 1:400, OptiView DAB, Ventana Medical Systems, Inc., Tucson, Arizona, USA) and/or protein analysis (DAKO, clone 10E3, dilution 1:300, OptiView DAB). The expression of PSMA in all primary tumors and metastases was examined by ICH (DAKO, clone 3E6, dilution 1:40, Optiview DAB). All IHC analysis was performed with Ventana Benchmark Ultra (Ventana Medical Systems, Inc.). The definition of a lymph node was 'a nodular collection of lymphatic tissue including a sinus'. The size of the LNM was measured in mm by the longest axis. Lesions ≤ 2 mm were classified as micrometastases. All assessments were performed by one experienced, board-certified prostate pathologist who is section head of genito-urinary cancers histopathology (AP).

Ethics and approvals

This clinical study was approved by the Danish Health and Medicine Authority, The Danish Data Protection Agency, and the Northern Denmark Region Committee in Health Research Ethics (N-20140079). The protocol was registered in the EudraCT database (#2014-004210-28). All patients received written and oral information and signed a written informed consent form before inclusion in the study.

Statistics

Means, medians, and frequencies were used as descriptive statistics. The sensitivity, specificity, accuracy, positive predictive value (PPV), and negative predictive value (NPV) were calculated for patient-based and region-based analyses and reported with 95% confidence intervals (95% CI). Due to insufficient recruitment (20 recruited patients among 70 planned), analytical statistics were not used due to low statistical power.

Results

Patients

Twenty patients were enrolled in the trial (Table 1). All patients but one had EAU high-risk PCa. Seventeen patients underwent an MRI scan, while three patients underwent a PET scan with a diagnostic CT scan due to logistic/technical issues or medical device interference with MRI. The median time between ^{68}Ga-PSMA PET/CT and MRI/CT to surgery was 10 days. PET scanning and anatomical cross-sectional imaging were performed within 5 days in 19 of 20 patients. No adverse events were observed with ^{68}Ga-PSMA PET/CT as reported previously [18].

Pelvic imaging findings

All patients were positive at the prostate level on ^{68}Ga-PSMA PET/CT (18 positive and 2 equivocal). ^{68}Ga-PSMA PET/CT showed pathological uptake in the eLND area in 5/20 patients (25%) (3 positive and 2 equivocal) (Table 2). These five patients had nine PSMA-positive lesions (6 definitive and 3 equivocal lesions) in seven regions. Anatomical

Table 1 Patient demographics and characteristics

Number of patients	20
Age (years)	71 (58–76)
PSA level (ng/mL)	12.5 (2.8–66.0)
Gleason score	8 (7–9)
Clinical T-stage	
T1–T2	10
T3–T4	10
EAU risk class	
Intermediate-risk	1
High-risk	19
Histopathology	
Number of patients with lymph node metastasis	13 (65%)
Total number of LNs removed	573
LNs per patient	23 (12–62)
Number of positive LNs	33 (5.8%)
Number of anatomical regions	131
Number of positive regions	26 (19.1%)

Values are reported as numbers or medians with total ranges

EAU European Association of Urology, *LN* lymph node, *PSA* prostate-specific antigen

Table 2 Diagnostic characteristics of ^{68}Ga-PSMA PET/CT, morphological imaging (MRI/CT), and diffusion-weighted MRI of lymph nodes versus histopathological results

	Lymph node histopathology						Interpretation (with 95% confidence intervals)				
	Metastases			No metastases							
	M	E	B	M	E	B	Sensitivity (%)	Specificity (%)	PPV (%)	NPV (%)	Accuracy (%)
^{68}Ga-PSMA PET/CT											
Patient-based ($n=20$)	3	2	8	0	0	7					
E considered M							38.5 (13.9; 68.4)	100 (59.0; 100)	100 (NA)	46.7 (36.3; 57.4)	60.0 (36.1; 80.9)
E considered B							23.1 (5.0; 53.8)	100 (59.0; 100)	100 (NA)	41.2 (34.2; 48.5)	50.0 (27.2; 72.8)
Region-based ($n=131$)	3	1	22	2	1	102					
E considered M							15.4 (4.4; 34.9)	97.1 (91.9; 99.4)	57.1 (24.1; 84.8)	82.3 (79.7; 84.6)	80.9 (73.1; 87.3)
E considered B							11.5 (2.5; 30.2)	98.1 (93.3; 99.8)	60.0 (20.9; 89.5)	81.8 (79.5; 83.8)	80.9 (73.1; 87.3)
MRI/CT											
Patient-based ($n=20$)	1	0	12	0	0	7	7.7 (0.2; 36.0)	100 (59.0; 100)	100 (NA)	36.8 (33.3; 40.6)	40.0 (19.1; 64.0)
Region-based ($n=131$)	0	0	26	1	0	104	0.0 (0.0; 13.2)	99.1 (94.8; 100)	0 (NA)	80.0 (79.7; 80.3)	79.4 (71.5; 86.0)
DW-MRI											
Patient-based ($n=17$)	4	0	7	1	0	5	36.4 (5.0; 38.8)	83.3 (35.9; 99.6)	80.0 (36.2; 96.6)	41.8 (28.7; 55.9)	52.9 (27.8; 77.0)
Region-based ($n=110$)	4	0	19	3	0	84	17.4 (5.0; 38.8)	96.6 (90.3; 99.3)	57.1 (25.0; 84.7)	81.6 (78.5; 84.3)	80.0 (71.3; 87.0)

B benign, *DW* diffusion-weighted, *E* equivocal, *M* malignant, *MRI* magnetic resonance imaging, *NA* not available, *NPV* negative predictive value, *PET/CT* positron emission tomography/computed tomography, *PPV* positive predictive value, *PSMA* prostate-specific membrane antigen

imaging identified one LNM in one patient (5%) (Table 2). DW-MRI showed nine definitive LNMs located in seven regions in five (25%) patients (Table 2). An illustrative example is shown in Fig. 1.

Histopathology

Five hundred seventy-three lymph nodes were removed, of which 33 were LNMs found in 26 anatomical lymph node regions. Thirteen patients had LNM (13/20, 65%) (Table 1) proven by histopathology. Five patients presented with a single LNM, three patients had two LNMs, two patients had three LNMs, and three patients had 4–6 LNMs. On a patient basis, four patients presented with micrometastasis only, seven patients had LNM with the longest diameter between 2 and 10 mm, and only two patients had a largest LNM > 10 mm. Among the 33 positive LNMs, 8 were micrometastases, 13 had a longest diameter of 2–5 mm, 8 were 6–10 mm, 2 were 11–15 mm, 2 were 16–20 mm, and none was > 20 mm. All 33 LNMs were positive for PSMA immunostaining. All patients had positive PSMA immunostaining of the primary tumor.

Patient-based diagnostic performance

The sensitivity of ^{68}Ga-PSMA PET/CT was 39% while that for anatomical imaging was 8%. Please refer to Table 2 for 95% CI for diagnostic accuracy performance data. The specificity of both modalities was 100%, yielding an accuracy of 60% for ^{68}GA-PSMA PET/CT (50% with equivocal ^{68}Ga-PSMA PET/CT scans regarded as negative) versus 40% for MRI/CT. The PPV was 100% with both modalities, and the NPV ranged from 37 to 47%. DW-MRI showed a sensitivity, an accuracy, and an NPV very similar to those of ^{68}Ga-PSMA PET/CT, whereas the specificity and PPV were nominally lower than those of ^{68}Ga-PSMA PET/CT. There were no false-positive ^{68}Ga-PSMA PET/CT or MRI scans but one false-positive DW-MRI scan.

^{68}Ga-PSMA PET/CT was negative in all four patients (0%, 0/4) in whom the largest LNM was a micrometastasis but identified 3/7 (43%) patients with the largest LNM in the range of 2–10 mm on pathology and 2/2 (100%) patients with lymph nodes > 10 mm; the corresponding figures were 0/4 (0%), 1/7 (14%), and 0/2 (0%), respectively, with MRI/CT and 0/4 (0%), 3/7 (43%), and 1/2 (50%), respectively, with DW-MRI. Subgroup analysis was not planned or performed; diagnostic performance on an individual level is shown in Table 3.

Region-based diagnostic analyses

Each of the 20 patients had removal of 4–8 lymph node regions, corresponding to 131 lymph node regions. The region-based analysis, irrespective of imaging modality, showed inadequate diagnostic performance with sensitivities below 20% and PPVs only slightly above 50% (0% for MRI/CT) (Table 2). On the other hand, the NPVs were above 80% for all modalities. There were false positive lesions identified with all modalities at a regional level. The three true positive LNMs on ^{68}Ga-PSMA PET/CT were 9–11 mm in diameter, whereas the 30 false-negative LNMs on ^{68}Ga-PSMA PET/CT had a median diameter of 4 mm, with only 3 of 30 LNMs being larger than 10 mm.

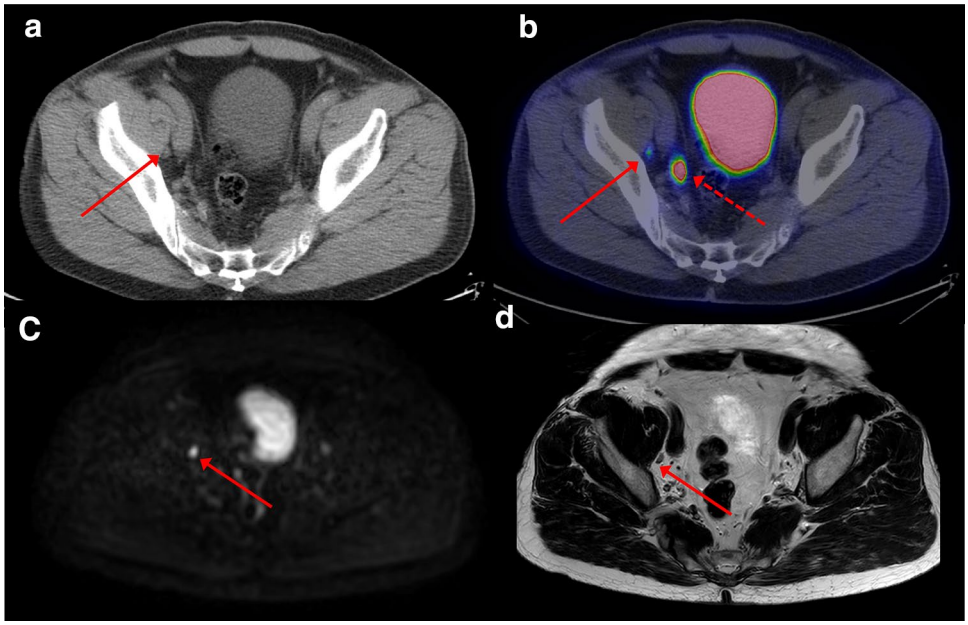

Fig. 1 Example of a patient with lymph node metastases on the right side of the pelvis on histopathology. One nonenlarged lymph node metastasis can be observed posterior to the iliac vessel on **a** CT (arrow). ^{68}Ga-PSMA PET/CT fused images **b** show markedly increased uptake in the lymph node (full arrow) and high uptake in the right ureter (hatched arrow). On DW-MRI, a high-intensity lesion (arrow) can be seen on the native DW (b600) image **c** corresponding to the nonenlarged lymph node seen in **d** the T2-weighted image (arrow)

Table 3 Patient-based summary of lymph node involvement and imaging performance on a patient level

Patient	PSA (ng/mL)	T stage	Gleason grade	EAU risk	MR/CT method	PSMA prostate	PSMA lymph node	MR/CT lymph node	DW-MRI lymph node	Pathology LNM	Largest LNM (mm)	PSMA patient[a]	MR/CT patient	DW-MRI patient
Ga-101	2.8	T3x	7 (4+3)	High	CT	Pos	Neg	Neg	–	Neg	–	TN	TN	–
Ga-102	9.8	T3x	7 (3+4)	High	MR	Eq	Eq	Neg	Neg	Pos	5	TP	FN	TN
Ga-103	25	T2a	8	High	MR	Pos	Neg	Neg	Neg	Pos	< 0.2	FN	FN	FN
Ga-104	23	T2c	9	High	MR	Pos	Neg	Neg	Neg	Pos	< 0.2	FN	FN	FN
Ga-105	11	T3x	7 (3+4)	High	MR	Pos	Neg	Neg	Neg	Neg	–	TN	TN	TN
Ga-106	5.7	T3b	8	High	MR	Pos	Neg	Neg	Neg	Neg	–	TN	TN	TN
Ga-108	66	T3x	7 (4+3)	High	CT	Pos	Neg	Neg	–	Pos	6	FN	FN	–
Ga-109	25	T2b	9	High	MR	Pos	Pos	Neg	Pos	Pos	7	TP	FN	FN
Ga-110	12	T2a	9	High	MR	Pos	Neg	Neg	Neg	Pos	< 0.2	FN	FN	FN
Ga-111	10	T1c	9	High	MR	Pos	Neg	Neg	Neg	Neg	–	TN	TN	TN
Ga-112	29	T3a	9	High	MR	Pos	Neg	Neg	Neg	Neg	–	TN	TN	TN
Ga-113	50	T2b	7 (4+3)	High	MR	Pos	Neg	Neg	Neg	Neg	–	TN	TN	TN
Ga-114	4.1	T3x	8	High	CT	Pos	Neg	Neg	–	Pos	< 0.2	FN	FN	FN
Ga-115	13	T3b	9	High	MR	Pos	Eq	Neg	Neg	Pos	16	TP	FN	FN
Ga-116	29	T1c	9	High	MR	Pos	Pos	Neg	Pos	Pos	11	TP	FN	FN
Ga-117	7.7	T3a	7 (4+3)	High	MR	Pos	Neg	Neg	Neg	Neg	–	TN	TN	TN
Ga-118	7.1	T2b	9	High	MR	Pos	Pos	Neg	Pos	Pos	8	TP	FN	FN
Ga-119	14	T2b	9	High	MR	Pos	Pos	Neg	Pos	Pos	10	TP	FN	FN
Ga-121	5.4	T2b	7 (4+3)	Int	MR	Eq	No	Neg	Neg	Pos	2	FN	FN	FN
Ga-122	21	T3x	7 (4+3)	High	MR	Pos	No	Pos	Neg	Pos	3	FN	TP	TP

CT computed tomography, *EAU* European Association of Urology, *Eq* equivocal, *FN* false negative, *Int* intermediate, *LMN* lymph node metastasis, *MR* magnetic resonance imaging, *Neg* negative, *Pos* positive, *PSA* prostate-specific antigen, *PSMA* prostate-specific membrane antigen, *TN* true negative, *TP* true positive

[a]Equivocal PSMA findings considered positive for calculation of diagnostic outcome

Imaging findings outside the area of eLND

Pathological PSMA uptake was observed in areas outside the eLND in two patients. Both patients also had PSMA-avid, pathology-verified LNMs in the eLND area. One patient had two positive lymph nodes localized in the left periclavicular region and in the mediastinum, and another patient had a lymph node at the level of the 5th lumbar vertebra. Both patients received hormonal therapy (bicalutamide) with significant and sustained prostate-specific antigen (PSA) responses until the last day of follow-up (July 2018). No follow-up imaging was performed. Neither MRI, CT nor DW-MRI detected any pathological lymph nodes outside the eLND area (the field of view was restricted to the pelvis and spine with DW-MRI). Suspected bone lesions were observed in one patient with ^{68}Ga-PSMA PET/CT and MRI and in six patients with DW-MRI. The bone data have recently been published separately [12]. No patients had any soft tissue metastasis identified on imaging.

Discussion

Investigation of any extraprostatic disease is key in the identification of patients eligible for curative or palliative treatment for PCa. This prospective, STARD-compliant trial comparing the diagnostic accuracy of ^{68}Ga-PSMA PET/CT versus guideline-recommended MRI/CT for primary lymph node staging showed a notable difference in sensitivity in favor of PET/CT over cross-sectional anatomical imaging. Although the sensitivity of PET/CT is equivalent to that of DW-MRI, its specificity is superior; furthermore, in combination with existing evidence of ^{68}Ga-PSMA PET/CT, this finding indicates that it may be reasonable to rethink the recommendations for lymph node staging to favor ^{68}Ga-PSMA PET/CT.

Cross-sectional anatomical imaging is generally recommended by urological organizations [1–3]. These recommendations are adhered to despite the documented poor diagnostic performance of cross-sectional anatomical imaging, with a weighted sensitivity less than 40% [4]. MRI and CT have very similar diagnostic performance for lymph node staging [4]. Thus, due to the low diagnostic performance of CT/MRI, laparoscopic eLND has been recommended in some countries prior to curative intent radiotherapy [19]. ^{68}Ga-PSMA PET/CT has recently been introduced for the detection of PCa. The status of this PET tracer for lymph node staging, with pathology as a reference, in intermediate- and high-risk PCa has been covered in comprehensive reviews [8, 20]. The proportion of patients with LNM was 65% (13/20 patients); prior trials have reported values in the range of < 30–60% [8, 10], with several trials showing values above 50% [21–23]. In general, the sensitivity of ^{68}Ga-PSMA PET/CT on a patient level was above 60% in most trials [8, 9]. Our data with a sensitivity of 39% were comparable to reports showing sensitivities of 33–38% [21, 24]. We reported a high proportion of patients with micrometastases and very small LNM, which negatively influenced sensitivity due to intrinsic resolution of the imaging methods. Many prior trials with primary staging have sparse data on the histopathological assessment and did not report LMN sizes. Some trials with ^{68}Ga-PSMA PET/CT had comparative data with MRI/CT; all these trials have shown superiority of PSMA imaging over anatomical imaging [22, 25, 26], as also shown in our study. Although our study showed that ^{68}Ga-PSMA PET/CT had modest sensitivity, it was notably better than the sensitivity of MRI/CT of 8%, which was a value similar to the MRI/CT data obtained at our institution nearly two decades ago [19]. We found that ^{68}Ga-PSMA PET/CT had an excellent specificity (similar to those of MRI/CT), which was comparable to previously reported values. The sensitivity with PET and MRI/CT was somewhat lower than those previously reported with ^{68}Ga-PSMA PET/CT [8, 9] and CT/MR [4].

DW-MRI was applied in our study as a secondary endpoint. The diagnostic performance of DW-MRI was comparable to that of ^{68}Ga-PSMA PET/CT except for the false positive findings, which decreased the specificity to approximately 80%. The sensitivity of DW-MRI of approximately 40% at the patient level was comparable to that in previous reports [27]. Our comparative findings of PET versus DW-MRI are in line with previous data. Zhang et al. compared ^{68}Ga-PSMA PET/CT with multiparametric MRI, including DW-MRI and dynamic contrast-enhanced MRI, and found very comparable results of the two imaging modalities [23]. Very recently, Park et al. reported data for ^{68}Ga-PSMA PET/CT compared with multiparametric MRI, but they reported PET data only for lymph nodes [28].

It remains speculative why there are major differences in the diagnostic performance of these imaging modalities across studies. Possible explanations are scanner-related issues, criteria for the definition of malignancy, histopathologic examination criteria and others. Our PET scanners were quite old. It cannot be ruled out that the intrinsic sensitivity would improve with better scanners. The criteria of classification of malignancy with functional methods (PET and DW-MRI) followed current reporting guidelines [16, 17]. A strict size criterion (> 10 mm) was used for MRI/CT. There were notable differences in the anatomical and functional criteria for lymph nodes to be declared malignant in prior trials, so we used a conservative approach [4, 29]. A similar size-only approach was used in other ^{68}Ga-PSMA PET/CT staging trials [22, 23].

The current practice is to identify potential metastatic deposits due to anatomically enlarged lymph nodes. However, our histopathology data showed, in general, very small

LNMs, including several patients with micrometastases and only two patients with LNMs with a diameter > 10 mm. Approximately 88% of the 33 LNMs were less than 10 mm in longest diameter. These data are in line with previous findings from trials with modern imaging modalities [29]. There were three true-positive LNMs identified on ^{68}Ga-PSMA PET/CT, with sizes of 9–11 mm, whereas the false-negative LNMs identified on ^{68}Ga-PSMA PET/CT had a median diameter of 4 mm. The vast majority of LNMs were < 10 mm in diameter. The mean size of histopathology-verified LNMs missed by ^{68}Ga-PSMA PET/CT have been reported to be approximately 4–5 mm [21]. Similarly, van Leeuwen et al. reported the sensitivity of ^{68}Ga-PSMA PET/CT to be 0% among LNMs ranging from 0 to 2 mm, 60% for LNM ranging from 2 to 5 mm in longest diameter, and 86% among LNMs larger than 5 mm [30]. Sixty-four percent of our LNM were < 6 mm in longest diameter. The small LNM sizes tested these diagnostic imaging modalities, particularly anatomical imaging, with size-based criteria for malignancy.

We are not aware of any prior studies that have assessed PSMA immunostaining of LNMs. It has been debated whether a minor proportion of patients have ^{68}Ga-PSMA PET/CT-negative primary tumors, which may hamper ^{68}Ga-PSMA PET/CT as a general imaging tool for PCa patients [25]. All 20 patients in this study had ^{68}Ga-PSMA-avid (18 definitive, 2 equivocal) primary tumors on PET/CT, and all primary tumors were confirmed to be PSMA-positive by IHC. Additionally, all 33 LNMs were positive on PSMA immunostaining. To the best of our knowledge, we are the first to report PSMA IHC data for LNM.

This study examined diagnostic performance of ^{68}Ga-PSMA for primary staging. The predominant application has been in secondary staging in patients with biochemical recurrence after curative prostatectomy or radiotherapy. Data have been shown in large retrospective studies, including studies with more than 1000 patients [6], large prospective trials with valid reference test [7], and recent systematic reviews and meta-analysis [8, 9]. The findings from primary staging cannot be compared to secondary settings due to various factors, including PSA levels at the time of examination and concomitant medication like androgen deprivation therapy [6].

This study was planned to include 70 patients, but we were only able to recruit 20 eligible patients; this was partly due long time to study start (GCP work) and due to competition from a Scandinavian radiotherapy protocol not allowing eLND prior to radiotherapy. This study has advantages and limitations which should be emphasized. The study was prospective in design, full STARD and GCP compliant; images and histology were read by experienced experts, and the reference was histopathology across all patients. The limitations were inadequate sample size due to recruitment issues, some variations in the surgeons performing the eLND (but reflecting clinical practice), and older PET/CT scanners without technical refinements like time-of-flight acquisition.

In conclusion, this prospective trial showed similar diagnostic performance of ^{68}Ga-PSMA PET/CT compared to DW-MRI and notably better sensitivity than anatomical imaging. Combined data in the public space suggest ^{68}Ga PSMA PET/CT to be the standard of care for the staging of high-risk PCa patients.

Author contributions LJP, HDZ, NCL, UH, and JBNP contributed to the conception and design of the study; JBN, NCL, AP, DTA, and JC contributed to the acquisition of data; HDZ, AAO, RVF, NMDS, and KDP evaluated the imaging data; LJP, JBN, and HDZ performed the analysis/interpretation of data; LJP, JBN, and HDZ drafted the manuscript. All authors critically revised the manuscript and approved the final version of the manuscript.

Funding The study was supported by an unrestricted Grant from the Obel Family Foundation (Grant no. 26063).

Availability of data and material The datasets used and/or analyzed during the current study are available from the corresponding author on reasonable request.

Compliance with ethical standards

Conflict of interest The authors declare that they have no competing interests.

Ethical approval This clinical study was approved by the Danish Health and Medicine Authority, the Danish Data Protection Agency, and the Northern Denmark Region Committee in Health Research Ethics (N-20140079). The protocol was registered in the EudraCT database (#2014-004210-28).

Consent to participate All patients received written and oral information and provided written informed consent.

References

1. Mottet N, Bellmunt J, Bolla M, Briers E, Cumberbatch MG, De Santis M, Fossati N, Gross T, Henry AM, Joniau S, Lam TB, Mason MD, Matveev VB, Moldovan PC, van den Bergh RC, Van den Broeck T, van der Poel HG, van der Kwast TH, Rouviere O, Schoots IG, Wiegel T, Cornford P (2017) EAU-ESTRO-SIOG guidelines on prostate cancer. Part 1: screening, diagnosis, and local treatment with curative intent. Eur Urol 71(4):618–629. https://doi.org/10.1016/j.eururo.2016.08.003
2. Carroll PH, Mohler JL (2018) NCCN guidelines updates: prostate cancer and prostate cancer early detection. J Natl Compr Cancer Netw 16(5s):620–623. https://doi.org/10.6004/jnccn.2018.0036
3. Sanda MG, Cadeddu JA, Kirkby E, Chen RC, Crispino T, Fontanarosa J, Freedland SJ, Greene K, Klotz LH, Makarov DV, Nelson JB, Rodrigues G, Sandler HM, Taplin ME, Treadwell JR (2018) Clinically localized prostate cancer: AUA/ASTRO/SUO guideline. Part II: recommended approaches and details of specific care options. J Urol 199(4):990–997. https://doi.org/10.1016/j.juro.2018.01.002

4. Hovels AM, Heesakkers RA, Adang EM, Jager GJ, Strum S, Hoogeveen YL, Severens JL, Barentsz JO (2008) The diagnostic accuracy of CT and MRI in the staging of pelvic lymph nodes in patients with prostate cancer: a meta-analysis. Clin Radiol 63(4):387–395. https://doi.org/10.1016/j.crad.2007.05.022
5. Eiber M, Maurer T, Souvatzoglou M, Beer AJ, Ruffani A, Haller B, Graner FP, Kubler H, Haberhorn U, Eisenhut M, Wester HJ, Gschwend JE, Schwaiger M (2015) Evaluation of hybrid ^{68}Ga-PSMA ligand PET/CT in 248 patients with biochemical recurrence after radical prostatectomy. J Nucl Med 56(5):668–674. https://doi.org/10.2967/jnumed.115.154153
6. Afshar-Oromieh A, Holland-Letz T, Giesel FL, Kratochwil C, Mier W, Haufe S, Debus N, Eder M, Eisenhut M, Schafer M, Neels O, Hohenfellner M, Kopka K, Kauczor HU, Debus J, Haberkorn U (2017) Diagnostic performance of ^{68}Ga-PSMA-11 (HBED-CC) PET/CT in patients with recurrent prostate cancer: evaluation in 1007 patients. Eur J Nucl Med Mol Imaging 44(8):1258–1268. https://doi.org/10.1007/s00259-017-3711-7
7. Fendler WP, Calais J, Eiber M, Flavell RR, Mishoe A, Feng FY, Nguyen HG, Reiter RE, Rettig MB, Okamoto S, Emmett L, Zacho HD, Ilhan H, Wetter A, Rischpler C, Schoder H, Burger IA, Gartmann J, Smith R, Small EJ, Slavik R, Carroll PR, Herrmann K, Czernin J, Hope TA (2019) Assessment of ^{68}Ga-PSMA-11 PET accuracy in localizing recurrent prostate cancer: a prospective single-arm clinical trial. JAMA Oncol. https://doi.org/10.1001/jamaoncol.2019.0096
8. Hope TA, Goodman JZ, Allen IE, Calais J, Fendler WP, Carroll PR (2018) Meta-analysis of ^{68}Ga-PSMA-11 PET accuracy for the detection of prostate cancer validated by histopathology. J Nucl Med. https://doi.org/10.2967/jnumed.118.219501
9. Perera M, Papa N, Roberts M, Williams M, Udovicich C, Vela I, Christidis D, Bolton D, Hofman MS, Lawrentschuk N, Murphy DG (2019) Gallium-68 prostate-specific membrane antigen positron emission tomography in advanced prostate cancer-updated diagnostic utility, sensitivity, specificity, and distribution of prostate-specific membrane antigen-avid lesions: a systematic review and meta-analysis. Eur Urol. https://doi.org/10.1016/j.eururo.2019.01.049
10. Petersen LJ, Zacho HD (2017) Gallium-68 prostate-specific membrane antigen positron emission tomography/computed tomography for staging of high-risk prostate cancer. Scand J Urol 51(6):498–501. https://doi.org/10.1080/21681805.2017.1354913
11. Bossuyt PM, Reitsma JB, Bruns DE, Gatsonis CA, Glasziou PP, Irwig LM, Lijmer JG, Moher D, Rennie D, de Vet HC, Standards for Reporting of Diagnostic A (2003) Towards complete and accurate reporting of studies of diagnostic accuracy: the STARD initiative. BMJ 326(7379):41–44
12. Zacho HD, Nielsen JB, Afshar-Oromieh A, Haberkorn U, deSouza N, De Paepe K, Dettmann K, Langkilde NC, Haarmark C, Fisker RV, Arp DT, Carl J, Jensen JB, Petersen LJ (2018) Prospective comparison of ^{68}Ga-PSMA PET/CT, ^{18}F-sodium fluoride PET/CT and diffusion weighted-MRI at for the detection of bone metastases in biochemically recurrent prostate cancer. Eur J Nucl Med Mol Imaging 45(11):1884–1897. https://doi.org/10.1007/s00259-018-4058-4
13. Barentsz JO, Richenberg J, Clements R, Choyke P, Verma S, Villeirs G, Rouviere O, Logager V, Fütterer JJ (2012) ESUR prostate MR guidelines 2012. Eur Radiol 22(4):746–757. https://doi.org/10.1007/s00330-011-2377-y
14. Fendler WP, Calais J, Allen-Auerbach M, Bluemel C, Eberhardt N, Emmett L, Gupta P, Hartenbach M, Hope TA, Okamoto S, Pfob CH, Poppel TD, Rischpler C, Schwarzenbock S, Stebner V, Unterrainer M, Zacho HD, Maurer T, Gratzke C, Crispin A, Czernin J, Herrmann K, Eiber M (2017) ^{68}Ga-PSMA-11 PET/CT interobserver agreement for prostate cancer assessments: an international multicenter prospective study. J Nucl Med 58(10):1617–1623. https://doi.org/10.2967/jnumed.117.190827
15. Lecouvet FE, Oprea-Lager DE, Liu Y, Ost P, Bidaut L, Collette L, Deroose CM, Goffin K, Herrmann K, Hoekstra OS, Kramer G, Lievens Y, Lopci E, Pasquier D, Petersen LJ, Talbot JN, Zacho H, Tombal B, deSouza NM (2018) Use of modern imaging methods to facilitate trials of metastasis-directed therapy for oligometastatic disease in prostate cancer: a consensus recommendation from the EORTC Imaging Group. Lancet Oncol 19(10):e534–e545. https://doi.org/10.1016/S1470-2045(18)30571-0
16. Rauscher I, Maurer T, Fendler WP, Sommer WH, Schwaiger M, Eiber M (2016) ^{68}Ga-PSMA ligand PET/CT in patients with prostate cancer: how we review and report. Cancer Imaging 16(1):14. https://doi.org/10.1186/s40644-016-0072-6
17. Padhani AR, Lecouvet FE, Tunariu N, Koh DM, De Keyzer F, Collins DJ, Sala E, Schlemmer HP, Petralia G, Vargas HA, Fanti S, Tombal HB, de Bono J (2017) METastasis reporting and data system for prostate cancer: practical guidelines for acquisition, interpretation, and reporting of whole-body magnetic resonance imaging-based evaluations of multiorgan involvement in advanced prostate cancer. Eur Urol 71(1):81–92. https://doi.org/10.1016/j.eururo.2016.05.033
18. Nielsen JB, Zacho HD, Haberkorn U, Nielsen KM, Dettmann K, Langkilde NC, Petersen LJ (2017) A comprehensive safety evaluation of 68 Ga-labeled ligand prostate-specific membrane antigen 11 PET/CT in prostate cancer: the results of 2 prospective, multicenter trials. Clin Nucl Med 42(7):520–524. https://doi.org/10.1097/RLU.0000000000001681
19. Borley N, Fabrin K, Sriprasad S, Mondaini N, Thompson P, Muir G, Poulsen J (2003) Laparoscopic pelvic lymph node dissection allows significantly more accurate staging in "high-risk" prostate cancer compared to MRI or CT. Scand J Urol Nephrol 37(5):382–386. https://doi.org/10.1080/00365590310006309
20. Han S, Woo S, Kim YJ, Suh CH (2018) Impact of ^{68}Ga-PSMA PET on the management of patients with prostate cancer: a systematic review and meta-analysis. Eur Urol. https://doi.org/10.1016/j.eururo.2018.03.030
21. Budaus L, Leyh-Bannurah SR, Salomon G, Michl U, Heinzer H, Huland H, Graefen M, Steuber T, Rosenbaum C (2016) Initial experience of ^{68}Ga-PSMA PET/CT imaging in high-risk prostate cancer patients prior to radical prostatectomy. Eur Urol 69(3):393–396. https://doi.org/10.1016/j.eururo.2015.06.010
22. Gupta M, Choudhury PS, Hazarika D, Rawal S (2017) A comparative study of ^{68}Gallium-prostate specific membrane antigen positron emission tomography–computed tomography and magnetic resonance imaging for lymph node staging in high risk prostate cancer patients: an initial experience. World J Nucl Med 16(3):186–191. https://doi.org/10.4103/1450-1147.207272
23. Zhang Q, Zang S, Zhang C, Fu Y, Lv X, Zhang Q, Deng Y, Zhang C, Luo R, Zhao X, Wang W, Wang F, Guo H (2017) Comparison of ^{68}Ga-PSMA-11 PET-CT with mpMRI for preoperative lymph node staging in patients with intermediate to high-risk prostate cancer. J Transl Med 15(1):230. https://doi.org/10.1186/s12967-017-1333-2
24. Yaxley JW, Raveenthiran S, Nouhaud FX, Samartunga H, Yaxley AJ, Coughlin G, Delahunt B, Egevad L, McEwan L, Wong D (2019) Outcomes of primary lymph node staging of intermediate and high risk prostate cancer with ^{68}Ga-PSMA positron emission tomography/computerized tomography compared to histological correlation of pelvic lymph node pathology. J Urol 201(4):815–820. https://doi.org/10.1097/ju.0000000000000053
25. Maurer T, Gschwend JE, Rauscher I, Souvatzoglou M, Haller B, Weirich G, Wester HJ, Heck M, Kubler H, Beer AJ, Schwaiger M, Eiber M (2016) Diagnostic efficacy of ^{68}Gallium-PSMA positron emission tomography compared to conventional imaging for lymph node staging of 130 consecutive patients with intermediate

to high risk prostate cancer. J Urol 195(5):1436–1443. https://doi.org/10.1016/j.juro.2015.12.025
26. Obek C, Doganca T, Demirci E, Ocak M, Kural AR, Yildirim A, Yucetas U, Demirdag C, Erdogan SM, Kabasakal L, Members of Urooncology Association T (2017) The accuracy of ^{68}Ga-PSMA PET/CT in primary lymph node staging in high-risk prostate cancer. Eur J Nucl Med Mol Imaging 44(11):1806–1812. https://doi.org/10.1007/s00259-017-3752-y
27. Van den Bergh L, Lerut E, Haustermans K, Deroose CM, Oyen R, Isebaert S, Budiharto T, Ameye F, Mottaghy FM, Bogaerts K, Van Poppel H, Joniau S (2015) Final analysis of a prospective trial on functional imaging for nodal staging in patients with prostate cancer at high risk for lymph node involvement. Urol Oncol 33(3):109. https://doi.org/10.1016/j.urolonc.2014.11.008
28. Park SY, Zacharias C, Harrison C, Fan RE, Kunder C, Hatami N, Giesel F, Ghanouni P, Daniel B, Loening AM, Sonn GA, Iagaru A (2018) Gallium 68 PSMA-11 PET/MR imaging in patients with intermediate- or high-risk prostate cancer. Radiology 288(2):495–505. https://doi.org/10.1148/radiol.2018172232
29. Thoeny HC, Froehlich JM, Triantafyllou M, Huesler J, Bains LJ, Vermathen P, Fleischmann A, Studer UE (2014) Metastases in normal-sized pelvic lymph nodes: detection with diffusion-weighted MR imaging. Radiology 273(1):125–135. https://doi.org/10.1148/radiol.14132921
30. van Leeuwen PJ, Emmett L, Ho B, Delprado W, Ting F, Nguyen Q, Stricker PD (2017) Prospective evaluation of ^{68}Gallium-prostate-specific membrane antigen positron emission tomography/computed tomography for preoperative lymph node staging in prostate cancer. BJU Int 119(2):209–215. https://doi.org/10.1111/bju.13540

Publisher's Note Springer Nature remains neutral with regard to jurisdictional claims in published maps and institutional affiliations.

Affiliations

Lars J. Petersen[1,2] · Julie B. Nielsen[1,2] · Niels C. Langkilde[2,3] · Astrid Petersen[4] · Ali Afshar-Oromieh[5] · Nandita M. De Souza[6] · Katja De Paepe[6] · Rune V. Fisker[1,7] · Dennis T. Arp[8] · Jesper Carl[8,9] · Uwe Haberkorn[10,11] · Helle D. Zacho[1,2]

Julie B. Nielsen
julie_boedker@hotmail.com

Niels C. Langkilde
ncl@rn.dk

Astrid Petersen
acp@rn.dk

Ali Afshar-Oromieh
a.afshar@gmx.de

Nandita M. De Souza
Nandita.Desouza@icr.ac.uk

Katja De Paepe
Katja.DePaepe@icr.ac.uk

Rune V. Fisker
rvf@rn.dk

Dennis T. Arp
deta@rn.dk

Jesper Carl
jespercarl@outlook.dk

Uwe Haberkorn
Uwe.Haberkorn@med.uni-heidelberg.de

Helle D. Zacho
h.zacho@rn.dk

1 Department of Nuclear Medicine, Aalborg University Hospital, Hobrovej 18-22, 9000 Aalborg, Denmark

2 Department of Clinical Medicine, Aalborg University, Aalborg, Denmark

3 Department of Urology, Aalborg University Hospital, Aalborg, Denmark

4 Department of Pathology, Aalborg University Hospital, Aalborg, Denmark

5 Department of Nuclear Medicine, Bern University Hospital, Bern, Switzerland

6 The Institute of Cancer Research and Royal Marsden NHS Foundation Trust, London, UK

7 Department of Radiology, Aalborg University Hospital, Aalborg, Denmark

8 Department of Medical Physics, Aalborg University Hospital, Aalborg, Denmark

9 Department of Oncology, Naestved Sygehus, Zealand University Hospital, Naestved, Denmark

10 Department of Nuclear Medicine, University Hospital Heidelberg, Heidelberg, Germany

11 Clinical Cooperation Unit Nuclear Medicine, DKFZ, Heidelberg, Germany